



"Bill" - Cairn Terrier with Enlarged Prostate



"Bill" first presented at Fairfield with problems with his "waterworks"! Not only did he have blood in his urine but he was passing small quantities some times without appearing to realise.

The rather awkward examination for both patient and vet via his rectum revealed an enlarged prostate gland. This is a very common finding in older male dogs and humans for that matter!

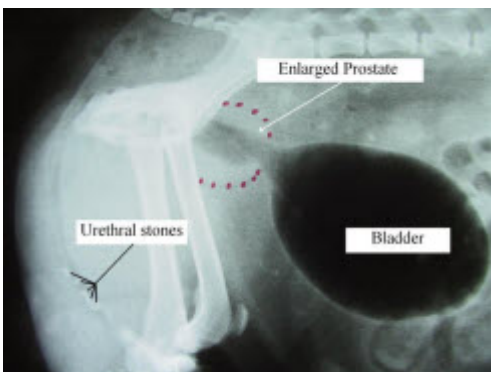
Over a number of years the prostate gland which is situated at the neck of the bladder can become enlarged. Consequently, it may affect the passage of urine through the urethra as it flows to the penis. This may occur directly through pressure or sometimes with associated inflammation if the prostate gland becomes infected.



Fortunately, in dogs, the treatment is very successful both with medication on a temporary basis and for a complete cure.....castration.

This is because it is the influence of testosterone on the prostate which makes it bigger. Remove the source of testosterone and the prostate should shrink in size! Prior to surgery it is often improved temporarily with drugs.

Despite initial treatment however, Bill failed to improve. Radiographs revealed the reason why. Not only did he have an enlarged prostate but a number of very uncomfortable stones in his urethra compounding his misery.



X-ray

A fairly extensive surgical procedure to remove the stones (urethrostomy) and the source of testosterone (castration) was performed. Despite some postoperative wound licking which delayed his recuperation "Bill" is well on the way to being his old self albeit with his "stones" missing!

Terry Dunne BVMS, Cert SAO, MRCVS