



Interesting Case from our web site www.fairfield-vets.co.uk



"Hedgehog" - Chorioptes Mites



It is a fairly frequent occurrence for hedgehogs to be brought into our surgery.

Usually they have been found injured or unwell, and are brought in for medical attention.

Our head nurse and a number of other clients also keep hedgehogs as pets - usually ones that have recovered from illness and are not suitable for release to the wild again. Thus, we consider ourselves to be fairly familiar with most hedgehog illnesses.

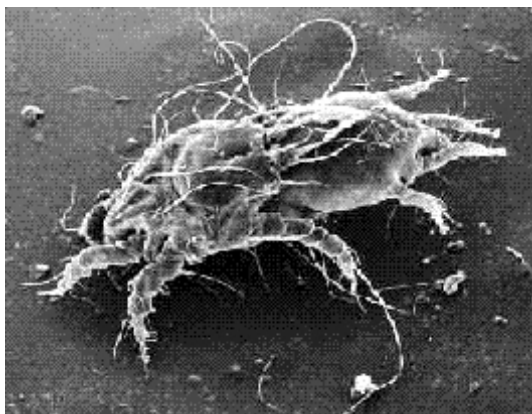
However, I was recently presented with a hedgehog whose condition was new to me. Mr. Hall, a keen hedgehog rescuer, who runs a unit for hedgehogs in need of care, brought in his most recent acquisition.

It was an adult female hedgehog, who seemed bright and chirpy in herself, but had extensive flaking over her skin surface, and loss of hair around her face.

Hedgehogs are renowned for carrying a number of parasites - fleas being the one that most of us are aware of! What you may be less aware of is that they are also frequent carriers of ringworm (though the carrier animal may have no symptoms itself).

They also have a high incidence of lungworm infection. One study showed that 66% of British hedgehogs were affected with this!

Ticks - which attach themselves as the hedgehog wanders through grass - are common. We have sometimes been presented with hedgehogs with 50 or more ticks attached! Thus, when a hedgehog arrives on our consulting table, we treat it with an anti-parasitic drug called Ivermectin as a matter of routine. This covers a multitude of sins!



When I examined Mr. Hall's hedgehog (or at least - the bits that weren't in the tight ball she had rolled into!) I could see no fleas or ticks, but on close examination, some of the flakes of scurf appeared to be moving!

I examined the flakes under a microscope and found that there were in fact hundreds of mites in them! Hedgehog mites belong to the Chorioptes species of mite - rarely seen in other domestic pets.

Infestation with them can be subclinical - that is - they are present in small numbers that don't show as full blown disease. This little hedgehog definitely had the fully monty, however! Fortunately, 3 doses of Ivermectin should cure her - a great relief I am sure - it must be incredibly frustrating when your own prickles stop you having a good scratch!

Geraldine Forsythe BVSC CertSAM MRCVS

This article is available on the Fairfield Veterinary Centre web site at www.fairfield-vets.co.uk

You won't care how much we know - until you know how much we care